

**INTERNATIONAL JOURNAL OF ADVANCES IN PHARMACY,
BIOLOGY AND CHEMISTRY****Research Article****Hepatoprotective activity of *Costus igneus* against
Paracetamol induced liver damage****Nimmy Chacko* and CS Shastry**Department of Pharmacology, NGSM Institute of Pharmaceutical Sciences, Paneer, Deralakatte, Manglore,
Karnataka, India.**ABSTRACT**

Costus igneus commonly known as Fiery costus or Spiral flag is a herbaceous plant. This plant is grown in America and is becoming popular in India because of its medicinal value. It is now accepted and used widely as an Ayurvedic medicinal herb. Paracetamol was used in a dose of 300mg/kg orally to induce hepatic damage. The induction of liver damage was confirmed by elevated serum enzyme levels and histopathological picture showing zonal focal necrosis. Administration of *Costus igneus* extract prior to acetaminophen administration effectively ($P < 0.05$) prevented the induction of damage by acetaminophen, which was confirmed by normal enzyme levels and lack of necrotic changes in the histopathological studies. The effect produced by 400mg/kg of *Costus igneus* was comparable with that produced by the standard drug silymarin.

1. INTRODUCTION

Liver diseases are posing as a major health problem around the world. Toxic chemicals, aflatoxins and water pollutants are major risk factors for liver diseases.¹ *Costus igneus* commonly known as Fiery costus or Spiral flag is a species of herbaceous plant. *Costus igneus* (Fam: Zingiberaceae) is a tropical evergreen shrub with large, smooth, dark green leaves. This plant is grown in America and is becoming popular in India because of its medicinal value. It is now accepted and used widely as an Ayurvedic medicinal herb. In south India, the leaves of *Costus igneus* is used to control blood sugar levels.

Drugs and chemicals induce liver toxicity. Drugs like acetaminophen, isoniazid, rifampicin, alcohol etc. are known hepatotoxins. Acetaminophen a widely used analgesic and antipyretic drug, produces acute liver damage in high doses. Acetaminophen administration causes necrosis of the centrilobular hepatocytes characterized by nuclear pyknosis and eosinophilic cytoplasm followed by large excessive hepatic lesion.² In spite of the tremendous advances in modern medicine no effective drugs are available, which stimulate liver functions and offers protection to the liver from damage or help to regenerate hepatic cells.³ On this basis, we took interest in studying effect of the leaves of *Costus igneus* on major organ like liver.

2. MATERIALS AND METHODS**2.1. Preparation of Ethanolic Extract**

The leaves of *Costus igneus* were collected from Puttur, Karnataka, India during June 2009. They were dried in shade. The shade dried powdered leaves (5kg) were soaked in ethanol (95%) and kept aside for four days. After four days the ethanol layer was decanted off. The Process was repeated for four times. The solvent of total extract was distilled off and concentrate was evaporated on a water bath to a syrupy consistency and evaporated to dryness.

2.2. Selection of animals

Wistar albino rats weighing between 180 – 200 g were selected for the acute toxicity and hepatoprotective. The animals were stabilized for 1 week and were given standard pellet diet and water ad-libitum throughout the course of the study.

3. Acute toxicity studies

The preliminary pharmacological studies were conducted to assess the acute pharmacological effects and LD50 of the ethanolic drug extract. The acute toxicity study was carried out in adult female albino rats by “up and down” method (OECD guidelines 425)⁴. The animals were fasted overnight and next day extracts of the plant *Costus igneus* (suspended in 0.6 % w/v sodium CMC) were administered orally at different dose level

(100mg/kg to 2000mg/kg). Then the animals were observed continuously for three hour for general behavioral, neurological, autonomic profiles and then every 30 min for next three hour and finally death after 24 hour.

4. Selection of doses

For the assessment of hepatoprotective activity, three dose levels were chosen in such a way that, middle dose was approximately one tenth of the maximum dose during acute toxicity studies, and a low dose, which was 50% of the one tenth dose, and a high dose, which was twice that of one tenth dose (100mg/kg, 200mg/kg, 400mg/kg).

5. Statistical Analysis

The data were expressed as mean \pm SEM. The data of hepatoprotective was analyzed by one way analysis of variance (ANOVA) followed by Dunnet's-'t' test. A p value less than 0.05 was considered as statistically significant.

6. Procedure for acetaminophen induced hepatotoxicity model

The experiment was carried out as according to the procedure described by E. Porchezian et. al.⁵ Wistar rats (180-200gm) of either sex, 7-8 weeks old were used; the rats were maintained at controlled temperature, 12 hrs light/12 hrs dark conditions for 1 week before the start of the experiment. Rats were divided into six groups of six animals in each group. Group I received saline (10ml/kg, i.p.) as normal control. Group II received Paracetamol, (3gm/kg.) orally in form of suspension with 0.6% C.M.C as treated control group on seventh day. Group III received silymarin suspended in 0.6% C.M.C (100mg/kg) orally as standard reference for seven days followed by acetaminophen administration on day seven. Group IV, V, VI received 100mg, 200mg, and 400mg/kg of ethanolic extract of *Costus igneus* suspended in 0.6% C.M.C for seven consecutive days followed by acetaminophen administration on day seven. The rats were sacrificed 48 hour after acetaminophen administration. They were anaesthetized by pentobarbital injection and blood was collected from vena cava, and serum was separated for assessment of different enzyme activities. The biochemical parameters like serum glutamate-pyruvate transaminase (ALT), glutamate

oxaloacetate transaminase (AST)⁶, alkaline phosphate (ALP)⁷, and total bilirubin⁸ were estimated using assay kits according to the methods described by the manufacturers. The rats were sacrificed by bleeding and liver was preserved into 10% formalin solution for histopathological investigation. The results were statistically analyzed by using one way analysis of variance (ANOVA), Followed by Dunnet's 't', test.

7. Discussion

Acute toxicity studies

The alcoholic extract of plant *Costus igneus* was found to be safe up to 2000 mg/kg body wt. by oral route. After 24hr animals were found well tolerated. There was no mortality and no signs of toxicity. So three dose levels i.e. 100mg/kg, 200mg/kg, and 400mg/kg body weight were selected for the present study.

Evaluation of Hepatoprotective activity

The alcoholic extract of the leaves of *Costus igneus* was used for the experiment. Paracetamol was used in a dose of 300mg/kg orally to induce hepatic damage.⁹ The induction of liver damage was confirmed by elevated serum enzyme levels and histopathological picture showing zonal focal necrosis. Silymarin was used as reference standard in a dose of 100mg/kg.¹⁰ Administration of *Costus igneus* extract prior to Paracetamol administration effectively (P< 0.05) prevented the induction of damage by Paracetamol, which was confirmed by normal enzyme levels and lack of necrotic changes in the histopathological studies. The effect produced by 400mg/kg of *Costus igneus* is comparable with that produced by the standard drug silymarin. In histopathological studies paracetamol treated group showed severe inflammation with focal necrosis. Liver tissues of rats pretreated with *Costus igneus* showed almost normal hepatocytes. It is concluded that alcoholic extract of *Costus igneus* was able to reverse the hepatotoxicity caused by Paracetamol.

ACKNOWLEDGEMENT

The author is thankful to Nitte Gulabi Shetty Memorial Institute of Pharmaceutical Sciences for providing necessary facilities to carry out this study.

Effect of Alcoholic extract of *Costus igneus* on PCML – induced in Hepatotoxicity in rats

SL.no	Treatments	SGPT	SGOT	ALP	TOTAL BILIRUBIN
1	Control	69.00 \pm 12.58	126.7 \pm 9.663	142.2 \pm 6.311	0.6983 \pm 0.1053
2	PCML	343.3 \pm 11.57*	383.8 \pm 11.31*	316.5 \pm 13.80*	3.313 \pm 0.1749*
3	PCML+Silymarin	77.50 \pm 8.480**	142.3 \pm 17.03**	154.2 \pm 7.752**	1.068 \pm 0.1077**
4	PCML+Drug 100mg	306.3 \pm 19.85	225.8 \pm 20.99	247.0 \pm 13.47	2.312 \pm 0.1645
5	PCML+Drug 200mg	157.5 \pm 9.698	179.7 \pm 16.16	178.3 \pm 5.200	1.492 \pm 0.1479
6	PCML+Drug 400mg	88.83 \pm 6.877**	152.3 \pm 12.48**	171.8 \pm 6.421**	1.455 \pm 0.0866**

Values are expressed as mean \pm SEM, n=rats in each group

*significant (P<0.05) compared to control, ** significant (P<0.05) compared to PCML group

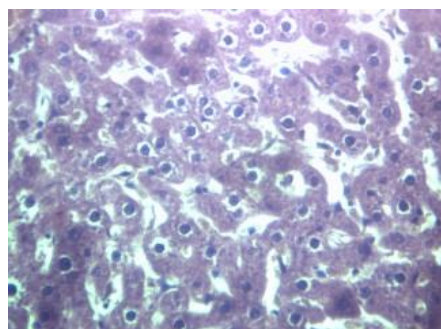


Fig. 1: Liver tissue: Control Group

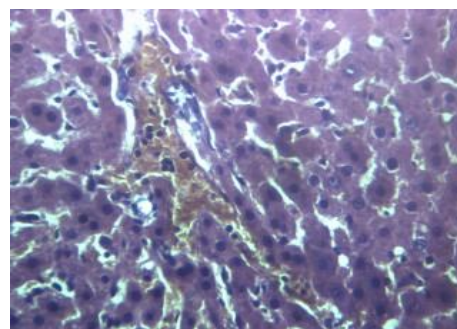


Fig. 2: Liver tissue: Paracetamol

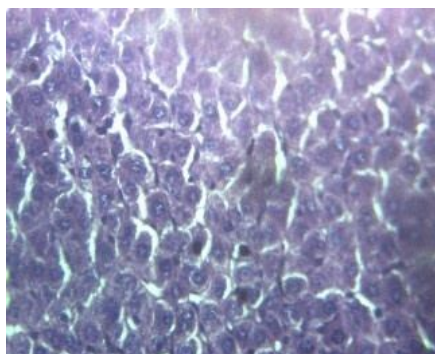


Fig. 3: Liver tissue: Silymarin Treated

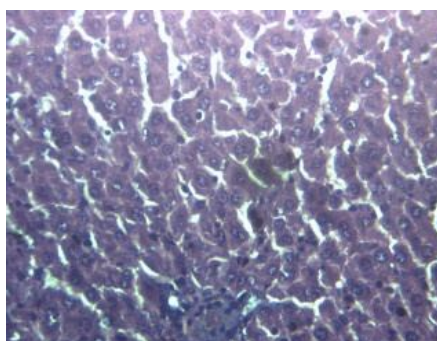



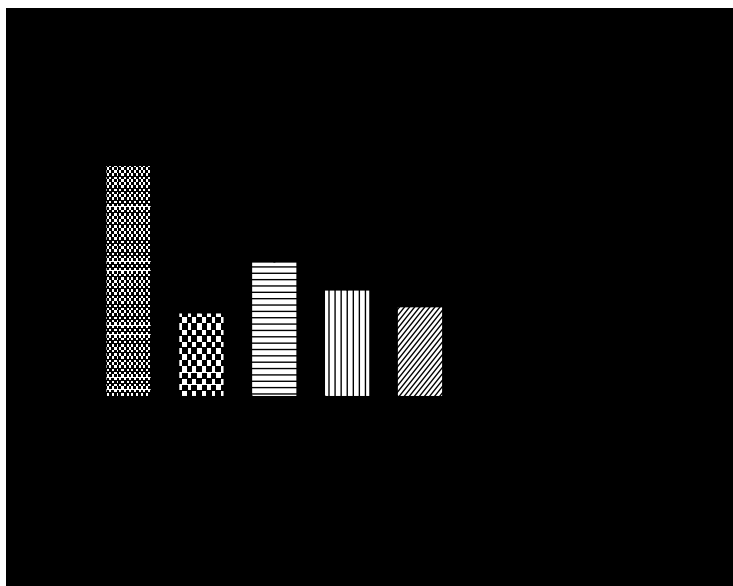


Fig. 4: Liver tissue: (400mg/kg extract)





REFERENCES

1. Paraskevi A and Ronald A. Hepatocellular carcinoma pathogenesis: From genes to environment, *Nat Rev Cancer*. 2006;6:674
2. Kanpur V, Dillai KK, Hussain SZ and Balani DK. Ind J Pharmacol. 1994;26(4):301-03
3. Chattopadhyay RR and Bandyopadhyay M. Possible Mechanism of Hepatoprotective Activity of Azadirachta indica Leaf Extract Against Paracetamol Induced Hepatic Damage in Rats: Part III. *Indian J Pharmacol*. 2005;37(3):185-185.
4. New OECD 425 Guidelines. ECD Guidelines for testing of Animals. 2001 1(26):1-26.
5. Porchezian E and Ansari SH. Hepatoprotective activity of Abutilon indicum on experimental liver damage in rats. *Phytomedicine*. 2005;12:62-64.
6. Reitman S and Frankel S. A colorimetric method for the determination of serum glutamate oxaloacetate transaminase, *Am J Clin Pathol*. 1957;28:56.
7. King J. The hydrolases- acid and alkaline phosphatases, in *Practical clinical enzymology* (nostrand Company Limited, London) 1965;191.
8. Malloy H T and Evelyln K A, the determination of bilirubin with the photometric colorimeter. *J Biol Chem*. 1937;119:481.
9. Goldin RD and Ratnayaka ID . Role of macrophages in acetaminophen (Paracetamol)-induced hepatotoxicity. 1996; 179(4):432–435
10. Pablo Muriel and Tania Garciapiña. Silymarin protects against paracetamol-induced lipid peroxidation and liver damage. *Journal of Applied Toxicology*. 1992;12(6):439-442.